



## Lines, tubes, and devices

Nasogastric tubes

### What will I gain from this video?

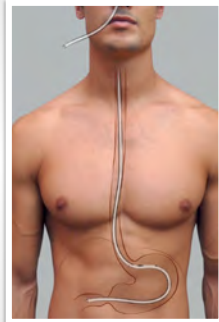
After watching this video, you will know how to determine the correct placement of nasogastric (NG) tubes.

### Nasogastric tubes

- NG Tube
- Dobhoff feeding tube

#### Path of NG insertion

- Nasal or oral cavity (nasal is shown)
- Pharynx
- Esophagus
- Stomach
- Duodenum



---

---

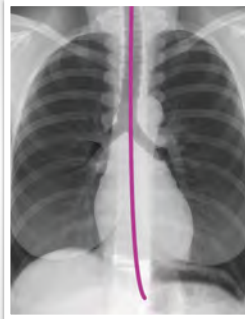---

---

---

---

#### Correct NG position



---

---

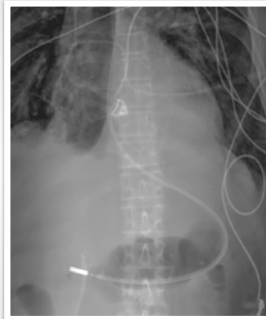---

---

---

---

#### Correct Dobhoff position



---

---

---

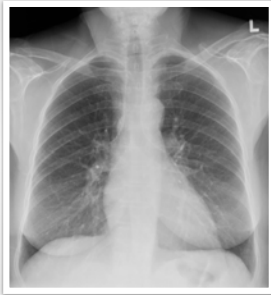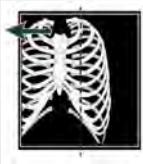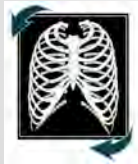---

---

---

How to assess for proper  
GI tube placement

STEP 1



---

---

---

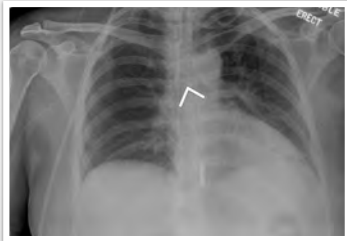---

---

---

How to assess for proper  
GI tube placement

STEP 2



---

---

---

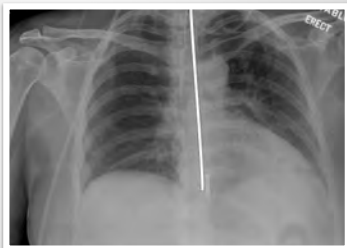---

---

---

How to assess for proper  
GI tube placement

STEP 3



---

---

---

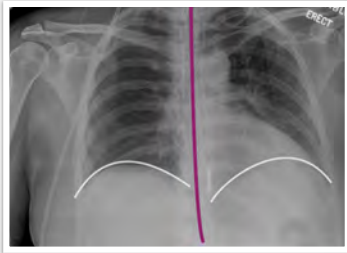
---

---

---

How to assess for proper  
GI tube placement

STEP 4



---

---

---

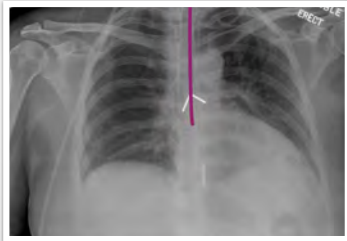
---

---

---

How to assess for proper  
GI tube placement

STEP 5



---

---

---

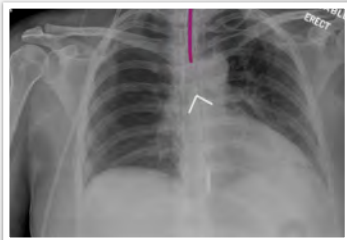
---

---

---

How to assess for proper  
GI tube placement

STEP 6



---

---

---

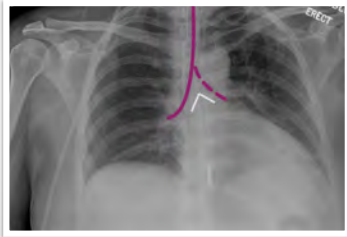
---

---

---

How to assess for proper  
GI tube placement

STEP 7



---

---

---

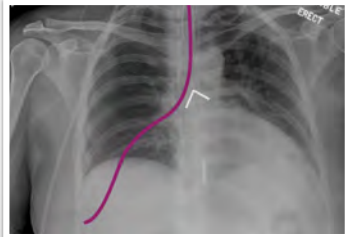
---

---

---

How to assess for proper  
GI tube placement

STEP 8



---

---

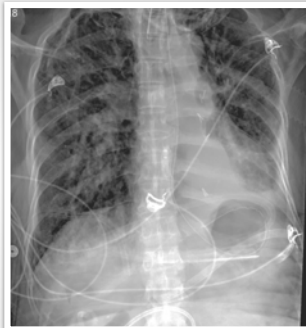---

---

---

---

Proper GI tube  
placement



---

---

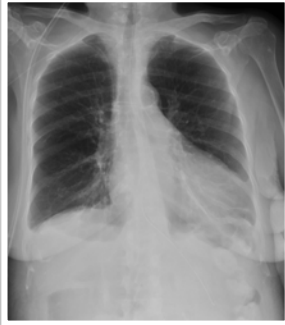---

---

---

---

**Proper GI tube placement**



---

---

---

---

---

Ideal NG tube position is below the hemidiaphragms within the stomach.

Ideal position of the tip of the Dobhoff tube is in the region of the antrum of the stomach, or in the duodenum.

---

---

---

---

---